

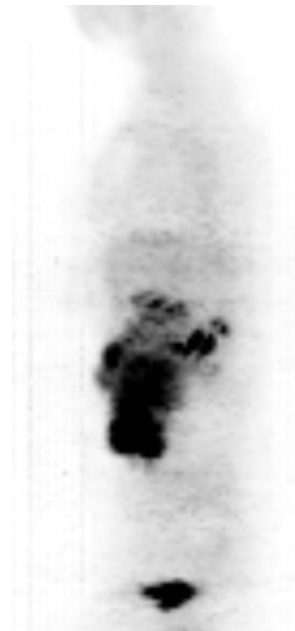Case

- 45 years old female
- Short history of abdominal pain, night sweats and weight loss
- Palpable abdominal mass
- Biopsy: DLBCL
- Stage: IIB
- NHL-IPI: Low risk
- Treatment in PETAL trial



PET

A
Pre-
treatment



SUV_{max}: 16,5

SUV_{max} reduction: ---

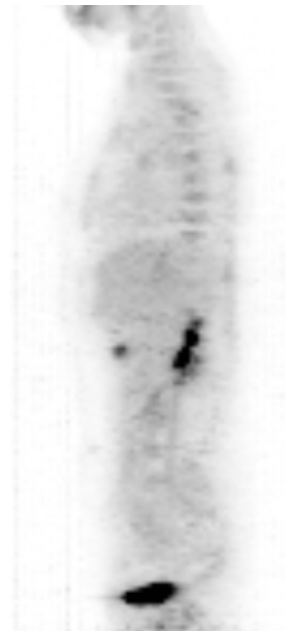
Visual score: positive

PET

A
Pre-
treatment



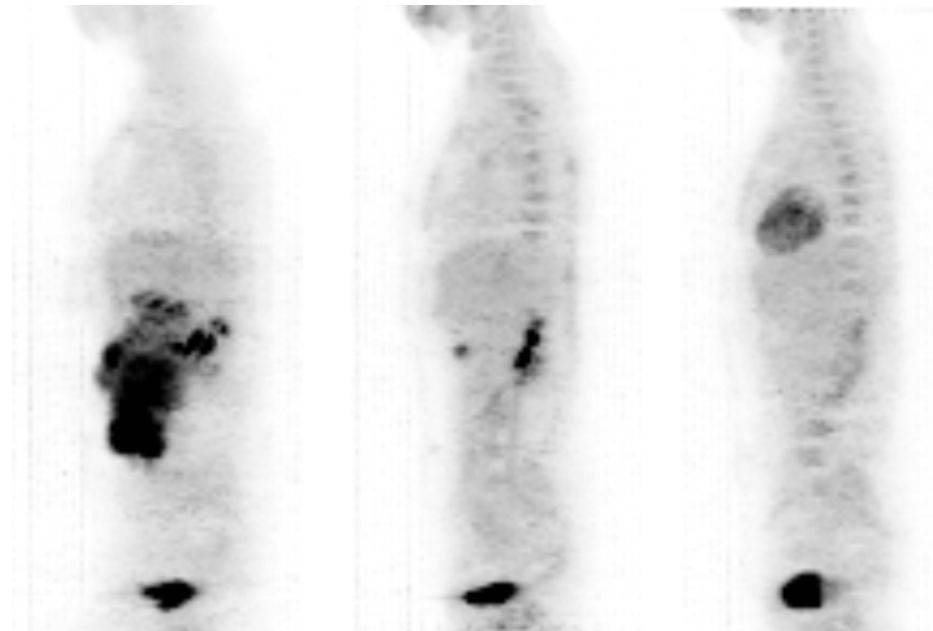
B
Interim
day 13



SUV _{max} :	16,5	7,3
SUV _{max} reduction:	---	56%
Visual score:	positive	positive

PET

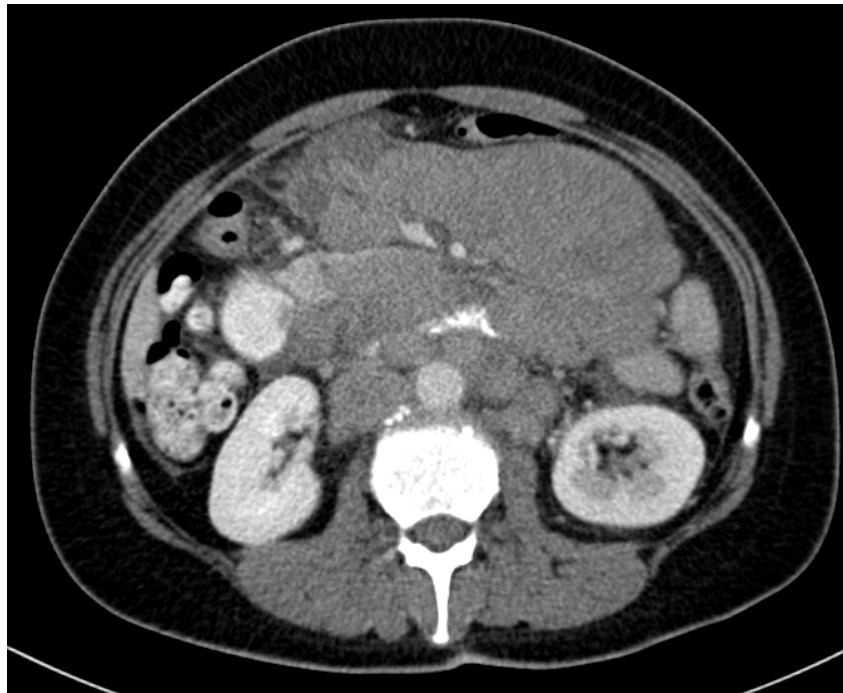
A	B	C
Pre- treatment	Interim day 13	Interim day 20



SUV _{max} :	16,5	7,3	2,8
SUV _{max} reduction:	---	56%	83%
Visual score:	positive	positive	negative

CT

Pre-treatment



Interim day 20

