

FDG PET/CT in pediatric lymphoma

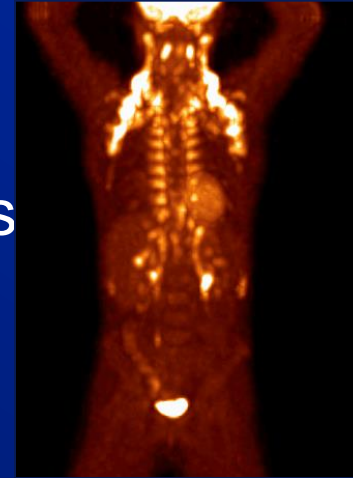
F. Montravers¹, V. Edeline²

Hôpital Tenon, Paris, France¹

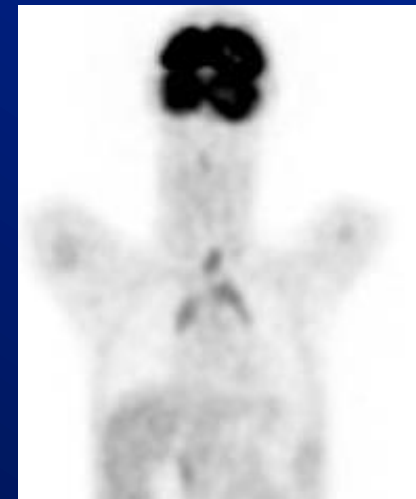Institut Curie Hôpital René Huguenin, Saint-Cloud,
France²

General considerations on FDG PET/CT in paediatric lymphoma

- Frequency of brown fat activation (prevention by unselective oral beta blockers recommended in the EuroNet trial)



- Frequency of physiologic uptake of thymus, pitfall: accessory gland



General considerations on FDG PET/CT in paediatric lymphoma

- Difficulty to schedule FDG PET for staging in NHL, due to the aggressiveness of disease and emergency of therapy

Hodgkin lymphoma: tumour characteristics and FDG uptake

- FDG avidity in 97-100% of cases in children and adults

(Elstrom et al. Blood 2003, Tsukamoto et al. Cancer 2007, Weiler-Sagie et al. J Nucl Med 2010)

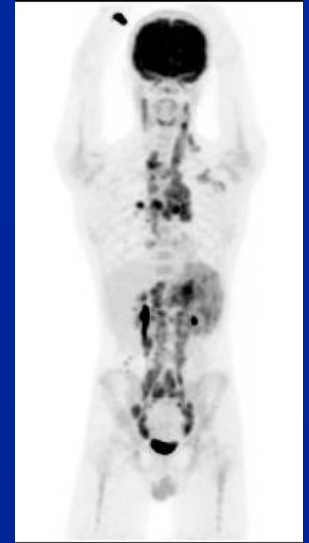
- FDG uptake is lower in lymphocyte-predominant HL (10% in children) than in classic HL

(Hutchings et al. Hematol Oncol. 2006)

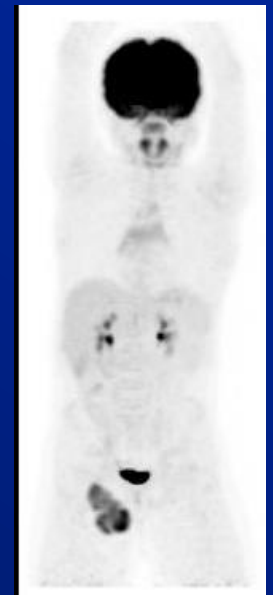
However, FDG PET is accurate

(Ansquer et al, Haematologica 2008,

Grellier et al, Eur J Nucl Med Mol Imaging, 2014)

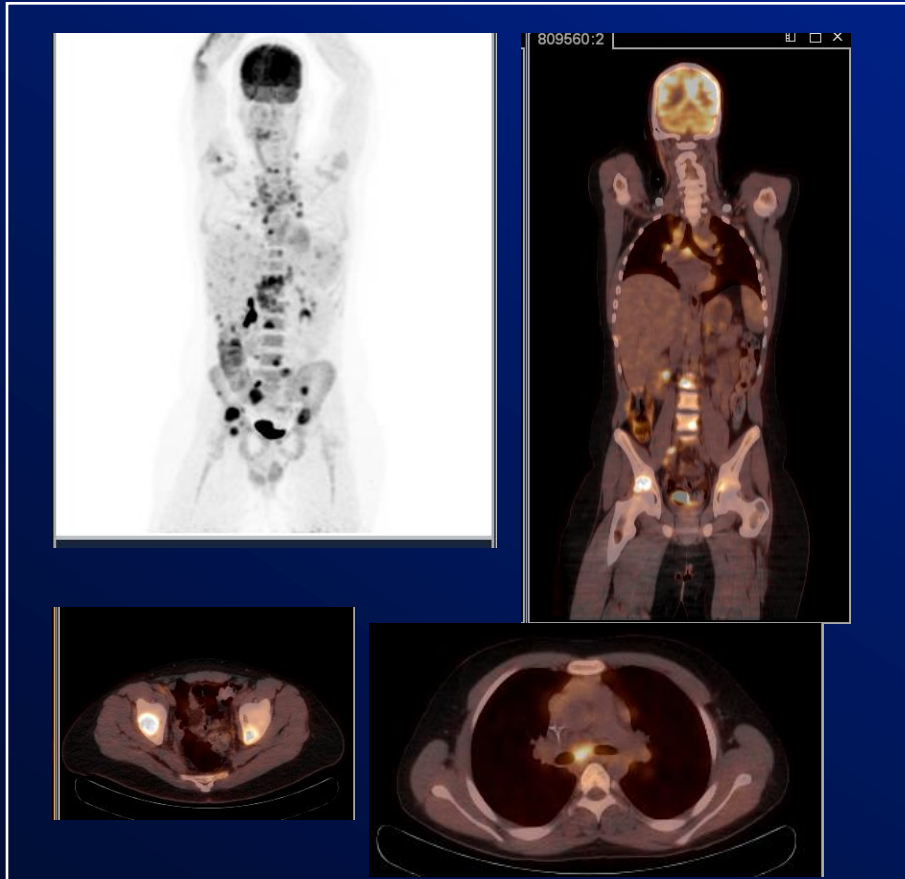


Classic HL

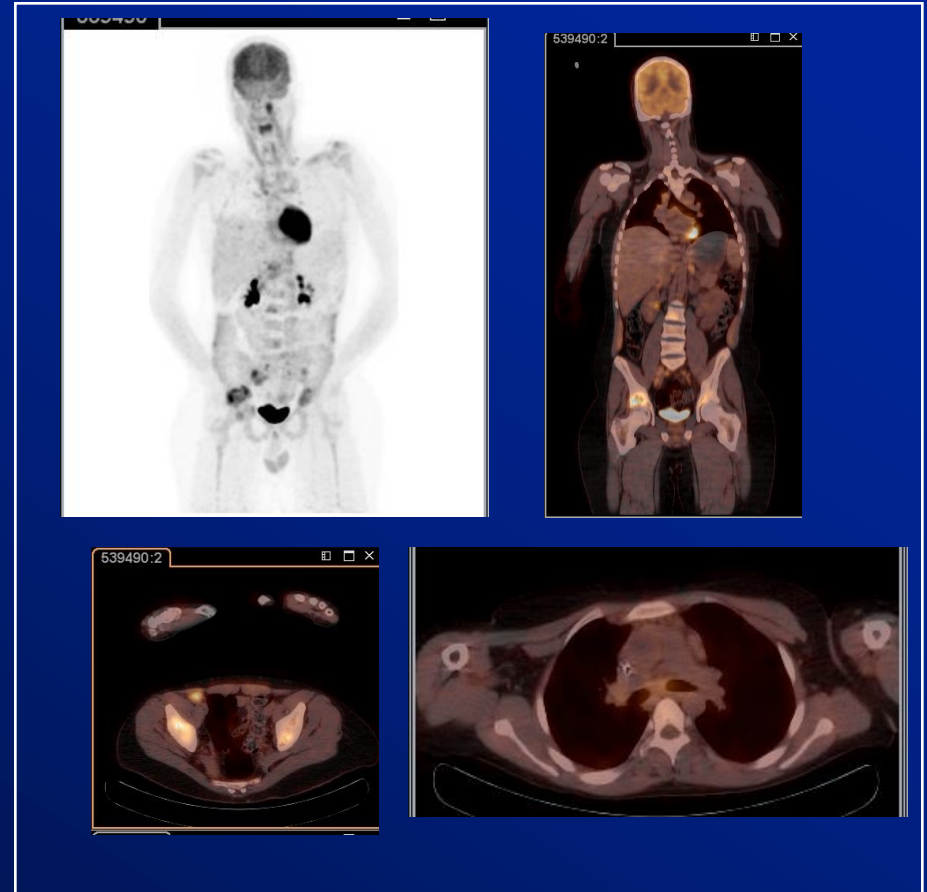


lymphocyte-predominant HL

In children with aggressive HL, requiring high dose corticosteroid therapy before chemotherapy, the baseline PET may be partly negativated after corticosteroids alone.



Baseline PET/CT

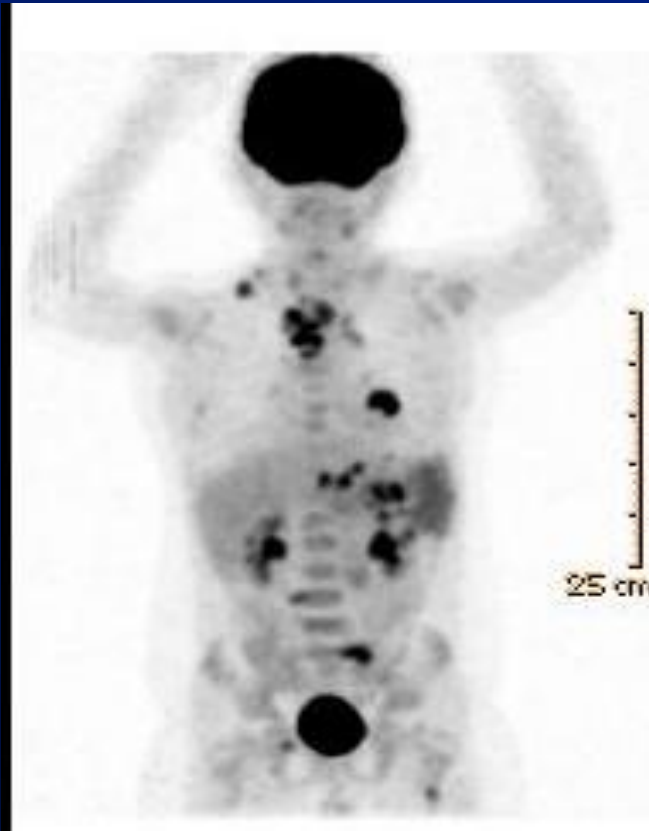

Second « baseline » PET/CT after corticosteroids alone

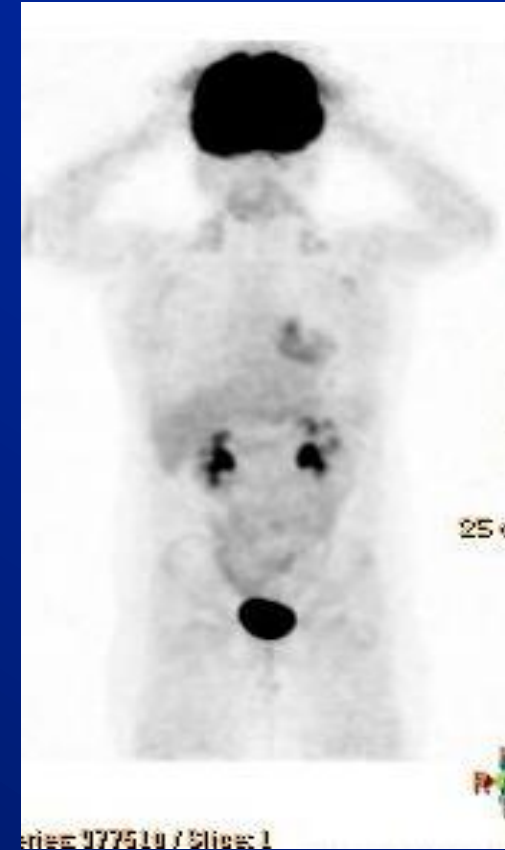
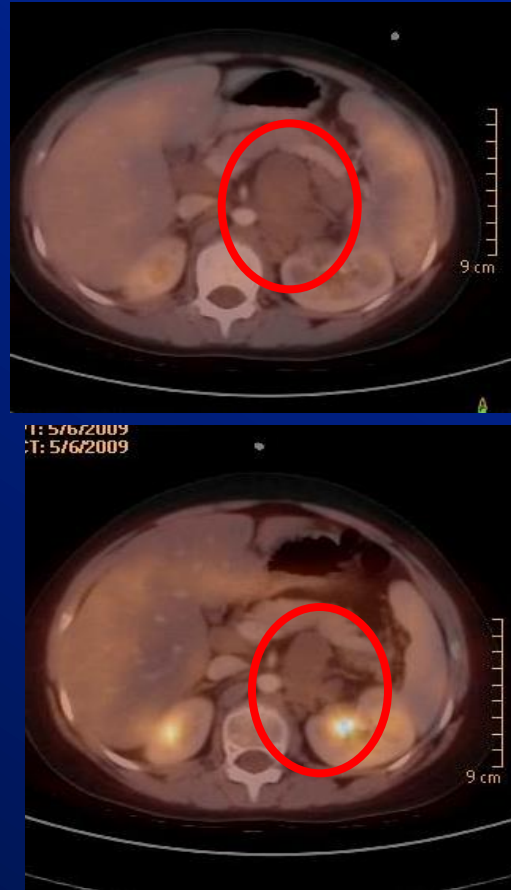
FDG PET/CT in staging childhood HL

- Superiority of FDG PET vs conventional methods in paediatric HL
(Kabickova et al, *Eur J Nucl Med Mol Imaging*, 2006 ; London et al, *Eur J Nucl Med Mol Imaging*, 2011)
- Higher sensitivity of FDG PET vs bone marrow biopsy in children
(Purz et al, *J Clin Oncol*, 2011) (In future EuroNet-PHL study, routine bone marrow biopsies will be replaced by FDG PET)

Importance to correlate FDG PET with the other imaging modalities



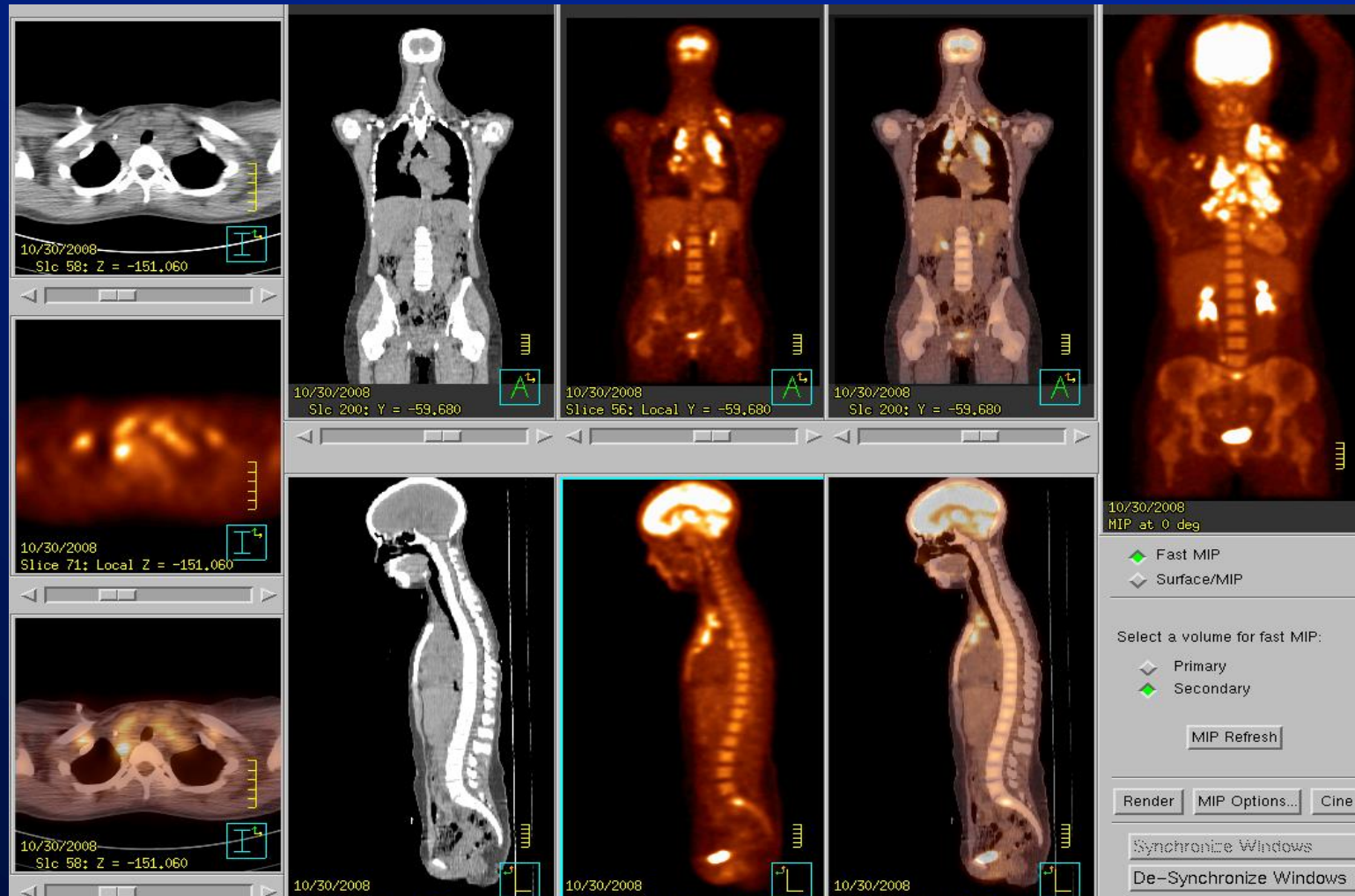
baseline



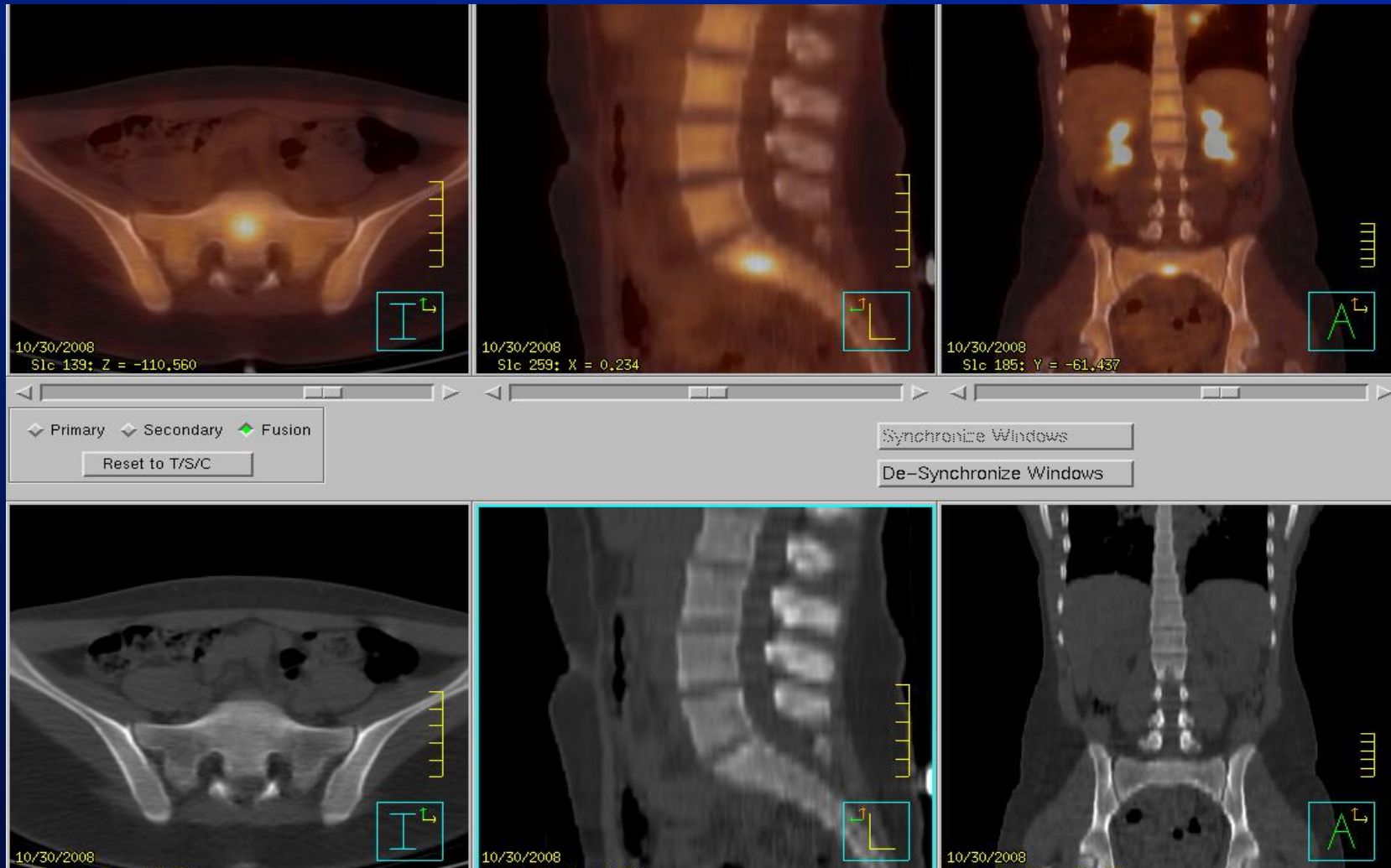
After 2 cycles of chemotherapy

Because in HL, some lesions can be non-FDG-avid. It is then very important to evaluate the volume reduction, which can be inadequate although the metabolic response is adequate.

Importance to correlate FDG PET with other imaging modalities

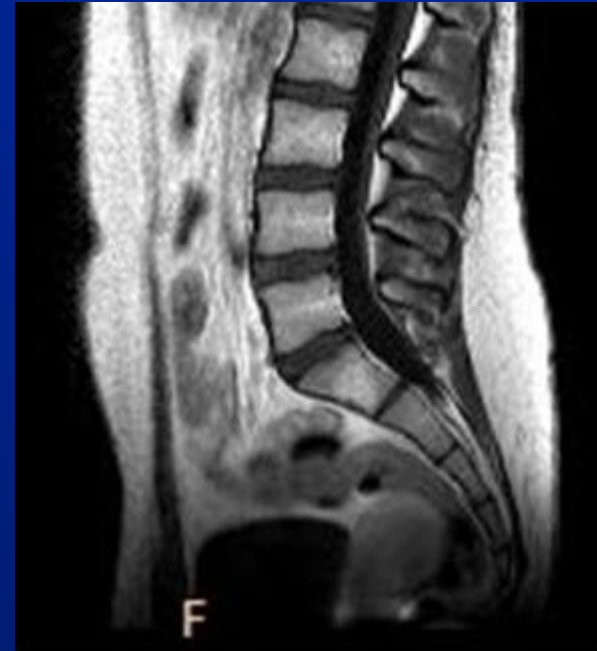
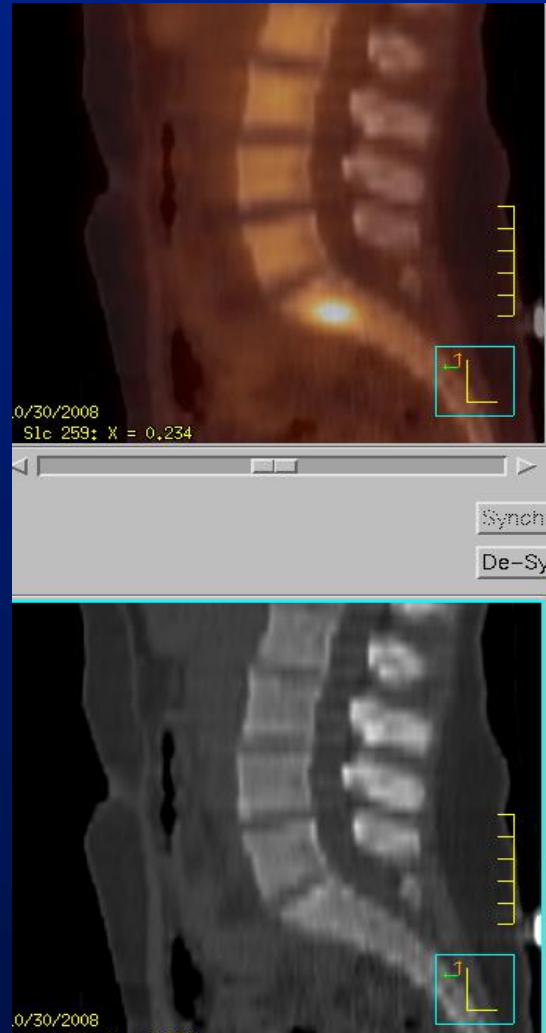
FDG uptake in the sacrum in a 14 year-old girl with HL staged II before PET



No abnormality on the corresponding CT

Importance to correlate FDG PET with another imaging modality



Confirmation of the sacral bone marrow involvement by MRI

=> Stage IV

Role of FDG PET in assessing therapy response in pediatric HL

crucial point which will be addressed in the next talk

FDG PET/CT and NHL in children

Pediatric Non-Hodgkin lymphoma comprises a broad heterogeneity of mostly aggressive high-grade lymphomas.

For example, Burkitt lymphoma is the fastest growing human tumour and doubles within 12-48 h

(Iversen et al, Eur J Cancer, 1974 ; Molyneux et al. Lancet, 2012).

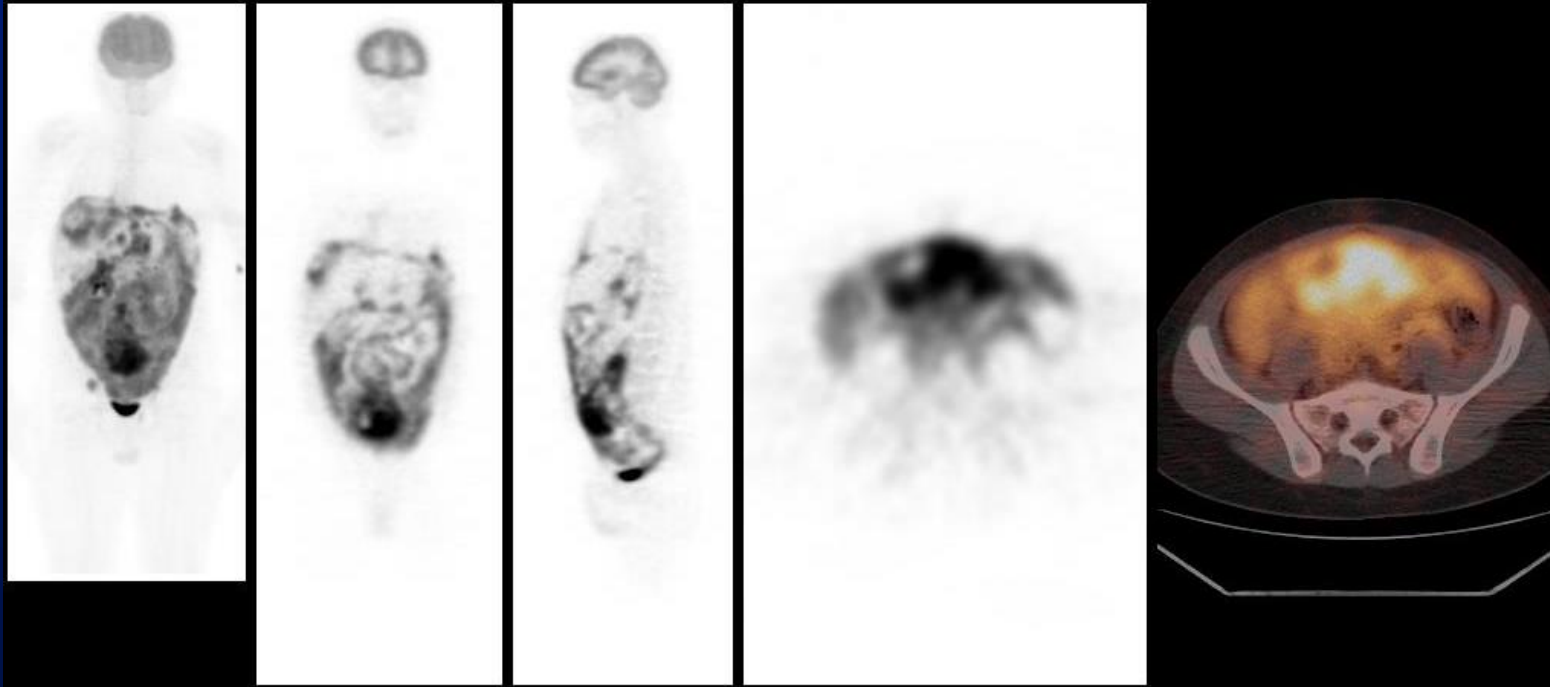
FDG PET/CT and NHL in children

Ongoing study in France on the role of FDG PET in staging and response assessment of pediatric NHL in comparison to conventional methods.

Some questions are:

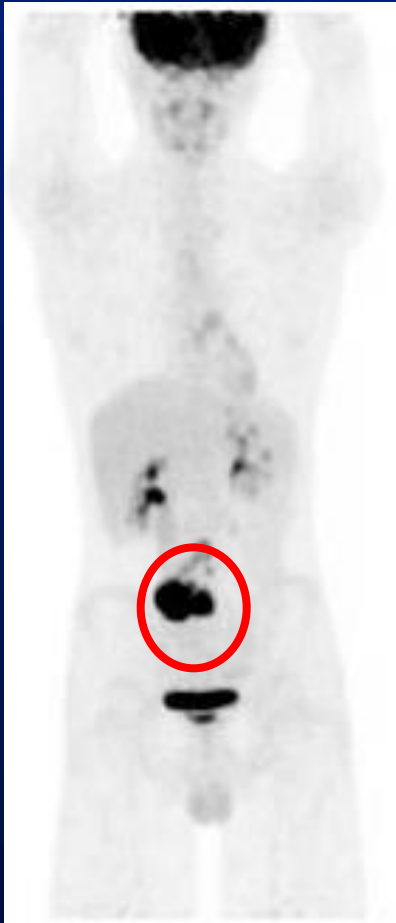- Are all the histologic subtypes FDG avid ?
- What is the performance of PET to detect extranodal disease, especially in kidneys and bone marrow ?
- Is an effective assessment of response possible in absence of initial PET ?
- Is FDG PET useful ?

The intensity of uptake is most often very high

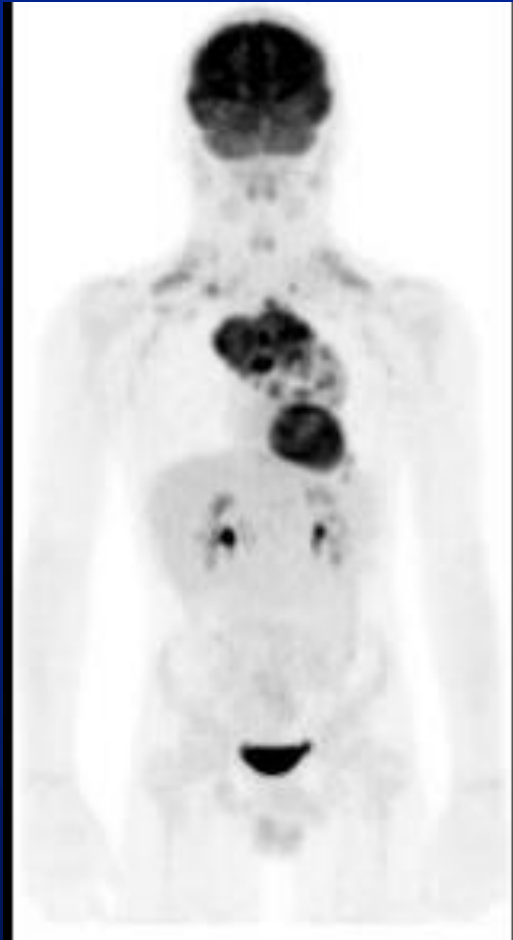


Burkitt lymphoma

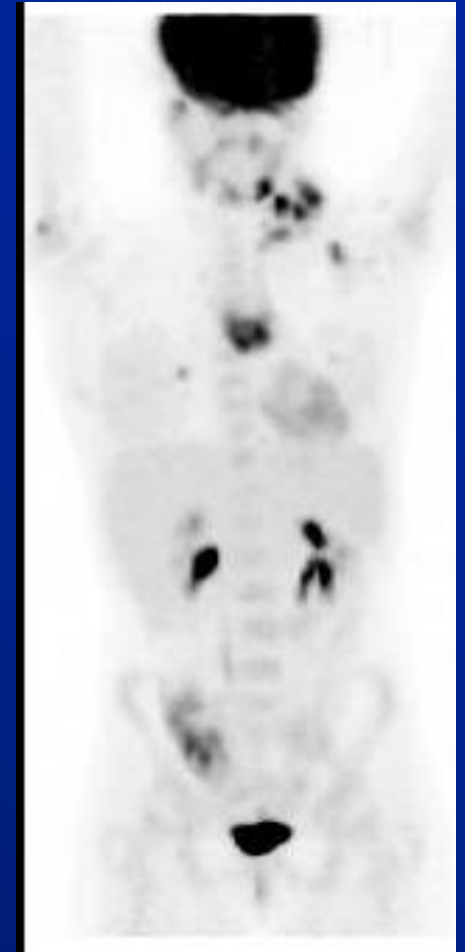The intensity of uptake is most often very high



Large B-cell lymphoma

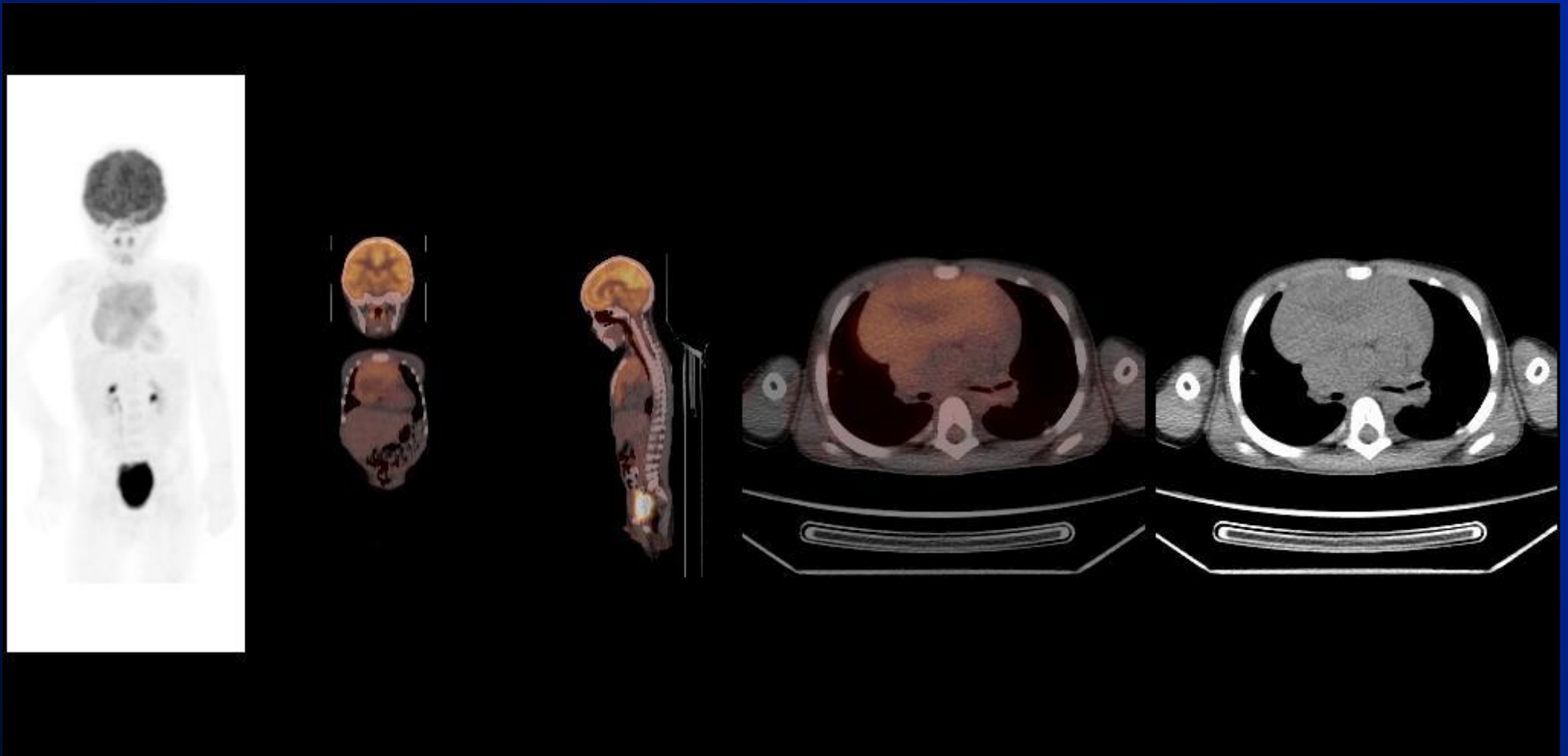


Primary mediastinal B-cell lymphoma



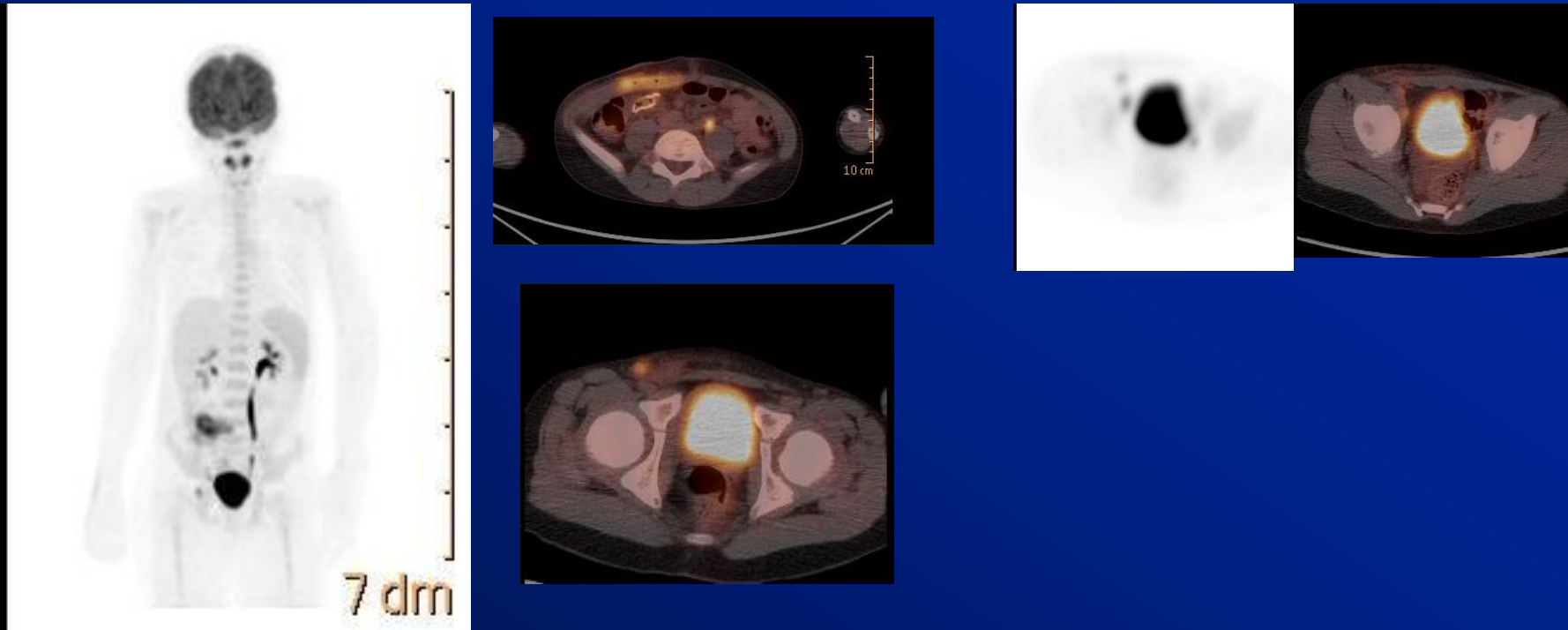
Anaplastic large-cell lymphoma

The intensity of uptake is usually very high
... but not always



Lymphoblastic T lymphoma

Difficult evaluation of response in absence of initial PET



Burkitt lymphoma revealed by two episodes of intestinal invagination in a 10 year old child.

PET performed one week after surgery. Abdominal wall uptake and lymph node uptakes probably post operative but inconclusive.

Conclusion

Important differences in histology, disease manifestation and treatment in HL and NHL in childhood

Today, FDG PET is recognised as an accurate imaging modality and is used for tailoring treatment intensity in children with HL

The role of FDG PET in NHL in children is not yet established and it will be the objective of the ongoing protocol in France to define it.